

Hurdles in the Diagnosis and Management of Chronic Pancreatitis

Prof. (DR.) MD. ISMAIL PATWARY

MBBS, FCPS, MD, FACP, FRCP(Glasgow, Edin)
Professor, Dept. of Medicine,
Sylhet women's Medical College, Sylhet

CHRONIC PANCREATITIS

Defined as a progressive inflammatory response of the pancreas that has led to irreversible and permanent changes

Parenchyma

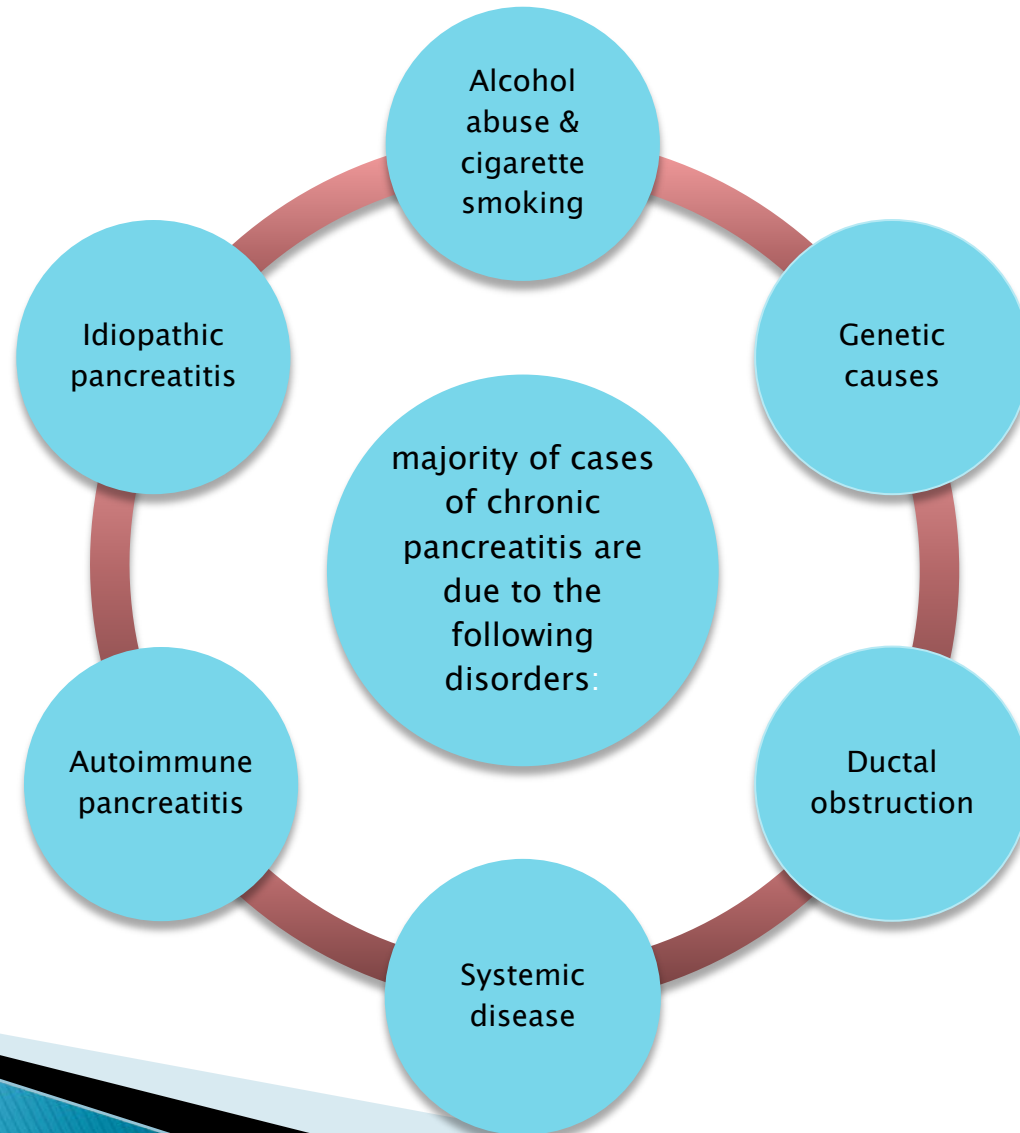
- Fibrosis
- Loss of acini and islets of Langerhans
- Formation of pancreatic stones

Pancreatic duct

- Stenosis
- Pancreatic stones

Histologic evidence of chronic inflammation, fibrosis, and destruction of exocrine (acinar cell) and endocrine (islets of Langerhans) tissue

Etiology



Diagnosis

History

Age

Abdominal pain

Weight loss
malnutrition

Nausea and
vomiting

Steatorrhea

Alcohol

Smoking

Family History

Drug History

History of
Acute
pancreatitis

DM

History of
Stones

Trauma

Surgical History

Systemic and
autoimmune
disorders

Clinical Manifestations

- * The two primary clinical manifestations of chronic pancreatitis are:

abdominal
pain

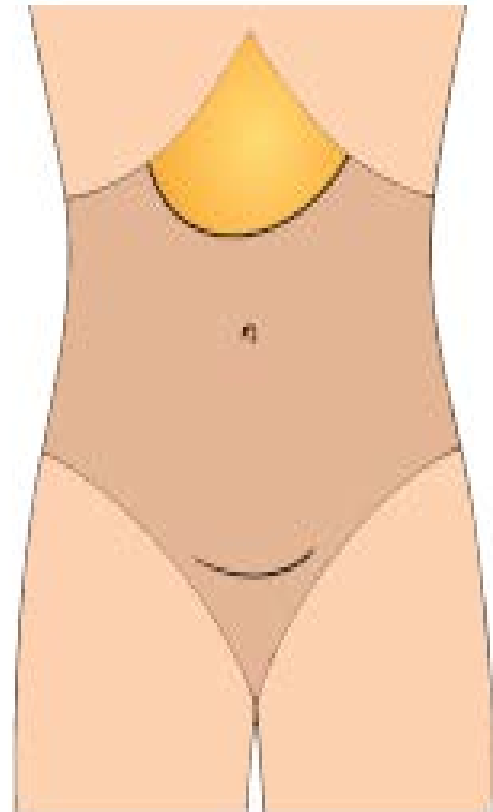
&

Pancreatic
insufficiency.

Clinical Manifestations

ABDOMINAL PAIN

- The pain is typically epigastric, often radiates to the back.
- Occasionally associated with nausea and vomiting, anorexia and weight loss
- Although abdominal pain is the most consistent finding in patients with chronic pancreatitis, it may be absent in some cases.

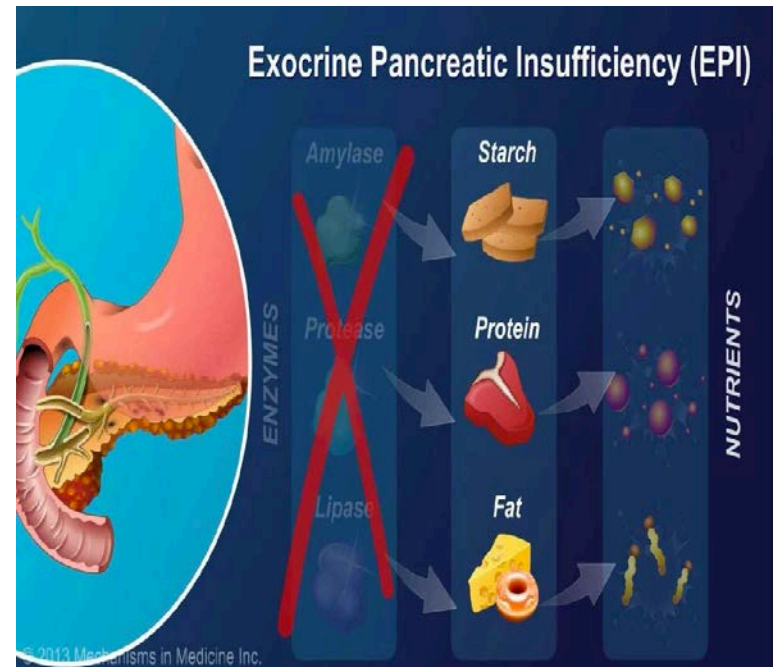


Patients report with chronic abdominal pain syndrome but normal pancreatic imaging tests , they have been incorrectly diagnosed, subjected to futile interventions, like ERCP with stent placement or narcotics for pain relief.

Clinical Manifestations

PANCREATIC INSUFFICIENCY

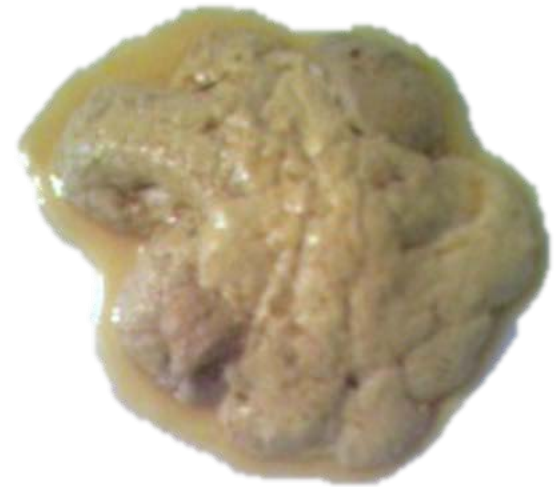- Patients with severe pancreatic exocrine dysfunction cannot properly digest complex foods or absorb partially digested breakdown products.
- Nevertheless, clinically significant protein and fat deficiencies do not occur until over 90 percent of pancreatic function is lost



Clinical Manifestations

FAT MALABSORPTION

- The clinical manifestations of fat malabsorption include loose, greasy, foul smelling stools that are difficult to flush.
- Malabsorption of the fat soluble vitamins (A, D, E, K) and vitamin B12 may also occur, although clinically symptomatic vitamin deficiency is rare.



steatorrhea

Clinical Manifestations

PANCREATIC DIABETES

- Glucose intolerance occurs with some frequency in chronic pancreatitis, but overt diabetes mellitus usually occurs late in the course of disease.
- Diabetes which develops in patients with chronic pancreatitis is usually insulin requiring.



Physical Examination

In most cases, the standard physical examination does not help to establish a diagnosis of chronic pancreatitis; however, a few points are noteworthy:

1. Epigastric tenderness during acute exacerbations.
2. In advanced cases, there may be an abdominal mass from a pseudocyst or pancreatic cancer, or splenomegaly from splenic vein thrombosis.
3. Patients with advanced disease (i.e, patients with steatorrhea) exhibit features of malnutrition.


Investigations

Serum Amylase and Lipase




- Levels may be elevated

Fecal Elastase



- Level will be abnormal in most cases

CBC, Electrolytes, and LFT



- Normal

A 72-hour Quantitative Fecal Fat Determination



- Gold standard for mal-absorption diagnosis

Autoimmune Markers



- ESR, IgG4, rheumatoid factor, ANA, and anti-smooth muscle antibody titre.

Gene Mutation Studies



- In selected cases in whom the etiology is uncertain

Investigations

Trans-abdominal ultrasound



- For initial assessment

Contrast CT



- shows calcifications, ductal dilatation, enlargement of the pancreas, and fluid collections (eg, pseudocysts) adjacent to the gland

MRCP



- Gold standard for diagnosis of pancreatitis

Diagnostic ERCP



- Has been replaced by MRCP

Endoscopic ultrasound



- If the diagnosis remains unclear after other imaging tests


- ▶ **ENDOSCOPIC ULTRASOUND (EUS):** To diagnose chronic pancreatitis requires the presence of at least 5 criteria of the followings:

<u>Parenchymal abnormalities</u>	<u>Hyperechoic foci</u>
	<u>Hyperechoic strands</u>
	<u>Lobularity of contour</u>
	Cysts
<u>Ductal abnormalities</u>	Main duct dilatation
	Main duct irregularity
	<u>Hyperechoic ductal walls</u>
	Visible side branches
	Calcification



- * Chronic pancreatitis, is a diagnostic dilemma.
- * Gold standard for diagnosis is pancreatic biopsy which is not a recommended practice for **safety issues**.

- MRCP and EUS are better alternatives.
MRCP replaced previously recommended ERCP.
- Faecal elastase-1 assay is one of many pancreatic function tests **but unpleasant.**

- * None of the above diagnostic tests is completely sensitive ('early' symptomatic cases may not be detected) or specific (test-positive cases without symptoms may not warrant active management).
 - * In clinical practice, therefore, a composite diagnosis based on clinical, morphological and functional criteria is more important.
- 

Complications

Pseudocyst
formation

Bile duct or
duodenal
obstruction

Pancreatic ascites

Pleural effusion,
& splenic vein
thrombosis

Pseudoaneurysms

pancreatic cancer

MANAGEMENT OF CHRONIC PANCREATIC PAIN



Management

* General treatment lines:

Lifestyle Modifications

Alcohol and smoking cessation

Dietary modifications “Low fat diet” and supplementations with medium chain triglycerides .



Pharmacologic Treatment

Analgesia “NSAIDs or Opioids”

PPI and pancreatic enzymes supplements.




Surgery

Pseudocyst decompression

Biliary or pancreatic duct decompression

Management usually starts with alcohol abstinence and smoking cessation though it is challenging because patients sometime drinks alcohol as a part of pain relief.

- ❖ Pain is the main symptom for which patients seek medical advice which accounts for most of the costs and greatest reductions in quality of life.
 - ❖ NSAIDS particularly opiate are used for pain relief with risk of addiction.
- 

MANAGEMENT OF PAIN

- ▶ **ESTABLISH A DIAGNOSIS**
- ▶ Other potential etiologies should be ruled out
 - Peptic ulcer disease
 - Biliary obstruction
 - Pseudocysts
 - Pancreatic carcinoma

Additional medical options for pain management include administration of

- **Pancreatic enzymes**
- **Octreotide**
- **Antioxidants**
- **Coeliac plexus neuronolysis**

Other Management includes

- **Endoscopic intervention**
 - **Surgery**
- 

- Coeliac plexus neuronolysis sometimes produces long-lasting pain relief **but relapse occurs in the majority of cases.**
- Endoscopic therapy includes Dilatation or stenting of pancreatic duct strictures, removal of calculi (mechanical or shock-wave lithotripsy), Drainage of pseudocysts **but facilities are not available in all centres and expensive.**

Surgical methods include

- * Partial pancreatic resection,
- * Pancreatico–jejunostomy.

This approach requires careful patient selection and detailed evaluation of pancreatic duct anatomy and chance of recurrence is also important factor.

- * Autoimmune chronic pancreatitis may require corticosteroid treatment which leads to various complications.
- * In some patients, MRCP does not show a surgically or endoscopically correctable abnormality and in these patients the only approach is total pancreatectomy.

- ❖ Unfortunately, even after this operation, some patients continue to experience pain.
- ❖ Moreover, the procedure causes diabetes, which may be difficult to control, with a high risk of hypoglycaemia and significant morbidity and mortality

Beside this diabetes, malabsorption (diarrhea, steatorrhea, weight loss, metabolic bone disease, or vitamin or mineral deficiency) and complications of chronic pancreatitis management is challenging.

Hurdles

May elude all conventional and modern diagnostic procedures



No early morning Alarm !!!!


Diagnosis is difficult at early part of the course

May progress even after having a firm diagnosis and being under follow up



Let's have a journey
with a young Lady with
many a hurdles

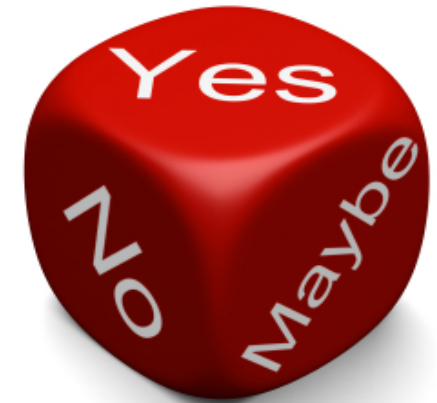

- ▶ A 25-year-old white woman presents had had 2 mild and self-limited episodes of well characterized acute pancreatitis at age 17.
 - ▶ She admitted to drinking alcohol most weekends, sometimes "bingeing," since age 16.
 - ▶ Her clinicians diagnosed alcoholic pancreatitis and advised abstinence.
- 


There may be hidden agenda



Is there any doubt for alcoholic pancreatitis?



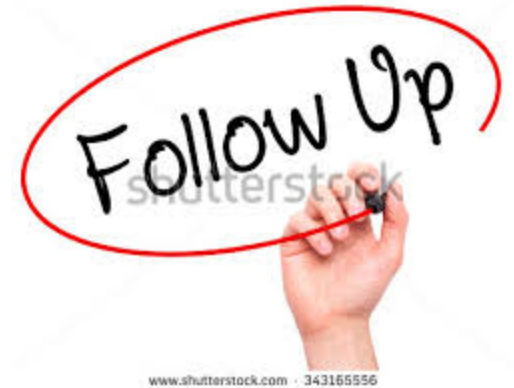- ▶ The rate of CP depends on alcohol consumption habits and varies from 3.5/100,000 to 27.4/100,000.
- ▶ Up to 75% of affected individuals are men.
- ▶ Most experts estimate that no more than 10% of chronic alcoholics develop CP

- ▶ **daily ingestion must be substantial over a long period**
 - ▶ **an intake of 80 grams of pure alcohol daily for 10 years is required for a patient to be firmly placed in the alcoholic cohort.**
 - ▶ **This equates to 1 bottle of wine or a 6-pack of beer daily for a decade**
- 

Let's follow her
up...

The woman was
asymptomatic for
2 years.

Then at age 20,
she had had 3
more discrete
episodes of clinical
acute pancreatitis.



Different thought

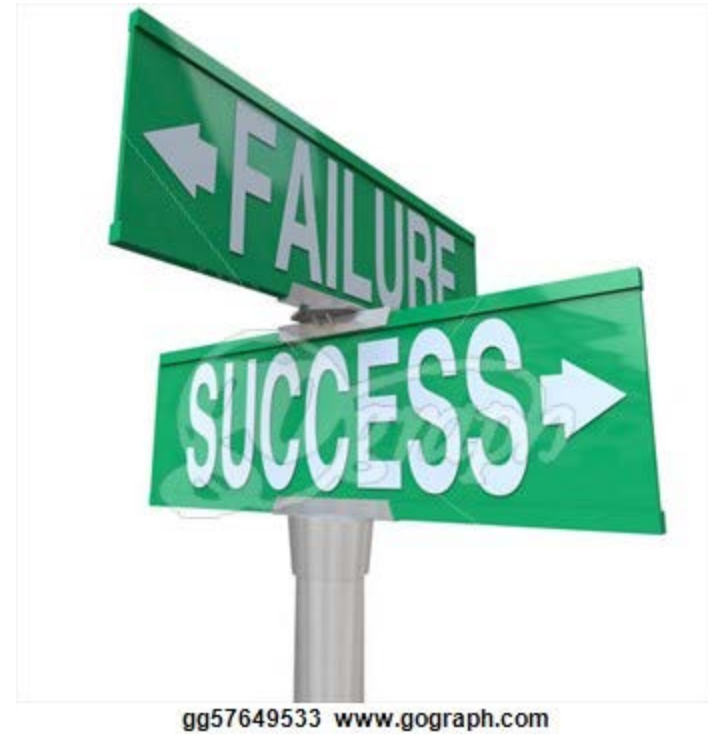- ▶ After the second episode, an empiric cholecystectomy was performed for possible microlithiasis
- ▶ Her episodes persisted.
- ▶ Her alcohol ingestion was now moderate: 3 to 4 beers at least 3 days/week.



Outcome?

- ▶ Frustrating !!!!
- ▶ She was still having the pain.

- ▶ She was again advised to discontinue alcohol,
- ▶ She complied without any substantial benefit.



Further shift

- ▶ Endoscopic retrograde cholangiopancreatography with pancreatic **sphincterotomies** was performed.
- ▶ A diagnosis of chronic pancreatitis (CP) secondary to **sphincter of Oddi dysfunction** was made.



Outcome: She got worse!!!!

- ▶ Despite complete alcohol abstinence, the woman had recurrent attacks of acute pancreatitis requiring hospitalization every other month (on average) for the next 4 years.



Step forward


- ▶ Routine physical exam, blood test, and abdominal computed tomography results are normal.





- ▶ **An endoscopic ultrasound demonstrates 6 criteria for CP:**
 1. hyperechoic strands and foci,
 2. parenchymal lobulation,
 3. small shadowing calcifications in the pancreatic head,
 4. an echogenic main duct wall,
 5. irregular main duct contour.

- ▶ **A diagnosis of idiopathic chronic pancreatitis (ICP) is established.**

Take Home messages

- ▶ Chronic pancreatitis is a chronic inflammatory condition with a poorly understood pathogenesis, multiple etiologies, and varied presentations ranging from abdominal pain to steatorrhoea.
 - ▶ Furthermore, for those who are recognized as having this disorder, the treatment has unfortunately been confusing and frustrating for clinicians and patients perspective.
- 

- ▶ Strategies to increase the accuracy of diagnosis, better assess symptoms and complications and manage patients using multidisciplinary teams (includes internists, gastroenterologists, surgeons, endocrinologists, dieticians, pain management, psychiatrists, social workers, and patient support groups) have improved the care of these patients.
- 

- ▶ Consistent delivery of the best evidence-based care has the potential to improve the health of many patients with chronic pancreatitis. Unfortunately, we still have many patients who remain symptomatic despite our best efforts.
 - ▶ So integrated measures should be taken for better management.
- 



THANK YOU